



Mallampati Score

Determining the Mallampati Classification:

The Mallampati classification relates tongue size to pharyngeal size and is an important factor in determining the degree of difficulty of direct laryngoscopy. This classification allows one to assess upper airway access based on visibility of the oral pharynx ranging from complete visualization including tonsillar pillars to no visualization with the uvula pressed against the tongue. This test is performed while the patient is in the sitting position, awake and cooperative. Simply have the patient open their mouth and stick out their tongue and assess based upon the pharyngeal structures that are visible. This may not always be possible to accomplish in our patients.

Class I: Visualization of the soft palate, fauces, uvula and pillars. No anticipated difficulty.

Class II: Visualization of the soft palate, fauces, uvula. No anticipated difficulty.

Class III: Visualization of the soft palate and base of the uvula. Anticipate moderate difficulty.

Class IV: Soft palate is not visible. Anticipate severe difficulty.

Mallampati Score

- Class I
 - visualization of the soft palate, fauces, uvula, and both anterior and posterior pillars
- Class II
 - visualization of the soft palate, fauces, and uvula
- Class III
 - visualization of the soft palate and the base of the uvula
- Class IV
 - soft palate is not visible at all

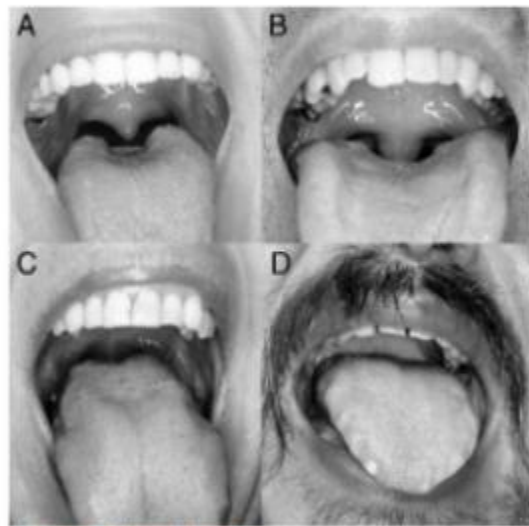


Figure 2: Mallampati views